






Proposal for International Standardization of the Use of Lung Ultrasound for Patients With COVID-19

A Simple, Quantitative, Reproducible Method

Gino Soldati, MD, Andrea Smargiassi, MD, PhD , Riccardo Inchingolo, MD , Danilo Buonsenso, MD , Tiziano Perrone, MD, PhD, Domenica Federica Briganti, MD, Stefano Perlini, MD, PhD, Elena Torri, MD, Alberto Mariani, MD, Elisa Eleonora Mossolani, MD, Francesco Tursi, MD, Federico Mento, MSc , Libertario Demi, PhD 

Received March 19, 2020, from the Diagnostic and Interventional Ultrasound Unit, Valle del Serchio General Hospital, Lucca, Italy (G.S.); Pulmonary Medicine Unit, Department of Cardiovascular and Thoracic Sciences (R.L.), and Department of Woman and Child Health and Public Health (D.B.), Fondazione Policlinico Universitario Agostino Gemelli, Istituto di Ricovero e Cura a Carattere Scientifico, Rome, Italy; Emergency Department, Fondazione Istituto di Ricovero e Cura a Carattere Scientifico, Policlinico San Matteo, and Department of Internal Medicine and Therapeutics, University of Pavia, Pavia, Italy (D.F.B. S.P.); Bressianamed, Brescia, Italy (E.T.); Unità Sabotaria Locale 118 Nordovest Toscana, Lucca, Italy (A.M.); Emergency Medicine Unit, General Hospital, Voghera, Italy (E.E.M.); Pulmonary Medicine Unit, Lodi General Hospital, Lodi, Italy (F.T.); Department of Information Engineering and Computer Science, Ultrasound Laboratory Trento, University of Trento, Trento, Italy (F.M., L.D.). Manuscript accepted for publication March 23, 2020.

Address correspondence to Libertario Demi, PhD, Department of Information Engineering and Computer Science, University of Trento, Via Sommarive 9, 38123 Povo, Trento, Italy.

E-mail: libertario.demi@unitn.it

Abbreviations
COVID-19, 2019 new coronavirus disease;
LUS, lung ultrasound; US, ultrasound

doi:10.1002/jum.15285

Growing evidence is showing the usefulness of lung ultrasound in patients with the 2019 new coronavirus disease (COVID-19). Severe acute respiratory syndrome coronavirus 2 has now spread in almost every country in the world. In this study, we share our experience and propose a standardized approach to optimize the use of lung ultrasound in patients with COVID-19. We focus on equipment, procedure, classification, and data sharing.

Key Words—COVID-19; lung ultrasound; point-of-care ultrasound; scoring system

A decade of clinical^{1–4} and physical studies^{5–9} clearly showed that lung ultrasound (LUS) is able to detect interstitial lung disease, subpleural consolidations, and acute respiratory distress syndrome from any etiologic cause. New evidence from published studies,^{10–12} national and international organization statements, and informal case discussions with internationally recognized experts are showing the usefulness of LUS for the management of patients with 2019 new coronavirus disease (COVID-19) pneumonia, from diagnosis to monitoring and follow-up.

To date, available medical treatments for COVID-19 pneumonia include anti-human immunodeficiency virus drugs, idrossicloroquine, ventilatory support, prone positioning, and extracorporeal membrane therapy for critical patients. However, recent findings suggest that anti-interleukin 6 monoclonal antibodies can be useful in blocking the inflammatory cascade involved in lung inflammation during COVID-19 infection. Evidence also suggests that the earlier we treat, the better patients improve with treatment.¹³ Therefore, LUS could be useful, being performed at several time points from clinical diagnosis, in determining early lung involvement during the paucisymptomatic phase of the disease and potentially playing a role in treatment decisions. Funding organizations are starting to support clinical trials; in this regard, LUS can be used to monitor lung involvement during a specific treatment. Importantly, LUS can be used in every setting, including low- to middle-income countries, allowing the reduction of disparities in trial participation, since

secondary-level imaging studies (such as computed tomography) are not easily accessible everywhere.

Therefore, this global emergency needs a global unified approach, with all researchers speaking the same language. For this reason, we propose a standardization for the international use of LUS for the management of patients with COVID-19.

Our LUS COVID team is made up of Italian experts in LUS currently involved in the clinical management of COVID-19 in different Italian areas, including the heavily involved cities of northern Italy. Moreover, experts in ultrasound (US) physics and image analysis are part of the team.

The team developed a standardized approach regarding equipment and the acquisition protocol. Moreover, the team proposed a scoring system for severity classification. To this aim, clinicians shared 30 cases of confirmed COVID-19 in an anonymized virtual database, for a total of about 60,000 frames to date. All team members discussed their clinical cases through online meetings. Images were reviewed by all team members, who were blinded to the clinical background, and listed in classes of the severity of lung involvement based on LUS images. At the end of this process, a biomedical engineer expert in LUS collected the data and suggested a LUS grading system for COVID-19 pneumonia. Again, the biomedical engineer resubmitted the images grouped in different classes of severity to the study members, who were blinded of clinical data, to review the images again and evaluated agreement regarding the LUS scores. The score was defined only when all team members agreed.

Methods

In the setting of COVID-19, wireless transducers and tablets represent the most appropriate US equipment. These devices can easily be wrapped in single-use plastic covers, reducing the risk of contamination and making sterilization procedures easy.¹⁴ Such devices are much less expensive than usual US machines, including the portable ones.

In cases of unavailability of these devices, portable machines dedicated to exclusive use for patients with COVID-19 can be used, although maximum care for sterilization is necessary. In these cases, transducer and

keyboard covers are suggested, and sterilization procedures are necessary, following recent recommendations.¹⁵

Sharing our real-world experience in performing LUS examinations in patients with COVID-19, we propose 2 different ways of performing LUS examinations with pocket devices, aiming to reduce the exposure of health workers to cases.¹⁴

One operator uses the transducer performing the US examination; the other one keeps the tablet and freezes images/videos. The second operator can be either in the room, being at a safe distance from the patient (about 2 m), or even remain outside the door, communicating by a phone call with the operator to optimize the quality of images. Potentially, this last approach can reduce the operator dependence of the US, since the second operator blindly selects the images, being unaware of the clinical condition of the patient. The 2 operators will follow an agreed, tested, and standardized images acquisition protocol.

Acquisition Protocol

Fourteen areas (3 posterior, 2 lateral, and 2 anterior) should be scanned per patient for 10 seconds along the lines indicated here. Scans need to be intercostal to cover the widest surface possible with a single scan.

A standard sequence of evaluations is proposed, using landmarks on chest anatomic lines (Figure 1). Echographic scans can be identified with progressive numbering starting from the right posterior basal regions. For a patient able to maintain the sitting position:

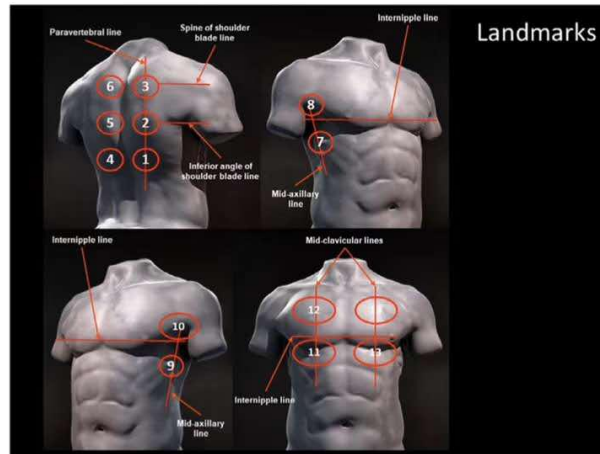
1. Right basal on the paravertebral line above the curtain sign;
2. Right middle on the paravertebral line at the inferior angle of the shoulder blade;
3. Right upper on the paravertebral line at the spine of the shoulder blade;
4. Left basal on the paravertebral line above the curtain sign;
5. Left middle on the paravertebral line at the inferior angle of the shoulder blade;
6. Left upper on the paravertebral line at the spine of the shoulder blade;
7. Right basal on the midaxillary line below the inter nipple line;

8. Right upper on the midaxillary line above the internipple line;
9. Left basal on the midaxillary line below the internipple line;
10. Left upper on the midaxillary line above the internipple line;
11. Right basal on the midclavicular line below the internipple line;
12. Right upper on the midclavicular line above the internipple line;
13. Left basal on the midclavicular line below the internipple line; and
14. Left upper on the midclavicular line above the internipple line.

In cases of performance of LUS examinations in critical care settings (such as patients receiving invasive ventilation) and for patients who are not able to maintain the sitting position, the posterior areas might be difficult to evaluate. In these cases, the operator should try to have a partial view of the posterior basal areas, currently considered “hot areas” for COVID-19 and, however, start the echographic assessment from landmark number 7.

- Use convex or linear transducers, according to the patient’s body size.
- Use a single-focal point modality (no multi-focusing), setting the focal point on the pleural line. Using a single focal point and setting it at the right location have the benefit of optimizing the beam shape for sensing the lung surface. At the focus, the beam has the smallest width and is therefore set to best respond to the smallest details.
- Keep the mechanical index low (start from 0.7 and reduce it further if allowed by the visual findings). High mechanical indices, used for a long observation time, may result in damage to the lung.¹⁶
- Avoid saturation phenomena as much as possible; control gain; and diminish the mechanical index if needed (see examples of LUS images in the figures). Saturation phenomena occur, eg, when the signal strength of the echo signals is too high for the receiving electronics to be converted into electrical signals, conserving a linear relationship with the pressure amplitude. This has the effect of distorting the signals and produces images where the dynamics of the actual signal are lost. The visual appearance of this phenomenon is the presence of

Figure 1. Schematic representation of the acquisition landmarks on chest anatomic lines.



areas that are completely white. In this case, it is therefore not possible to appreciate local variations in the response to insonations.

- Avoid the use of cosmetic filters and specific imaging modalities such as harmonic imaging, contrast, Doppler, and compounding.
- Achieve the highest frame rate possible (eg, no persistence and no multifocusing).
- Save the data in the Digital Imaging and Communications in Medicine format. In case this is not possible, save the data directly as a video format. Visual findings, especially when related to very small alterations, do not appear on every frame. It is thus advantageous to acquire videos, where the lung surface below the landmark can be monitored for a few seconds during breathing.

Scoring Procedures

- Score 0: The pleural line is continuous and regular. Horizontal artifacts are present. These artifacts are generally referred to as A-lines (See Figures 2–5). They are due to the high reflectivity of the normally aerated lung surface and characterize the

visual representation of the multiple reflections happening between the US transducer and the lung surface itself.^{3,5,7}

- Score 1: The pleural line is indented. Below the indent, vertical areas of white are visible. These are due to local alterations in the acoustical properties of the lung, as, for example, the replacement of volumes previously occupied by air in favor of media that are acoustically much more similar to the intercostal tissue (water, blood, and tissue). This phenomenon opens channels accessible to US, which can explain the appearance of the vertical artifacts.^{3,5,7}
- Score 2: The pleural line is broken. Below the breaking point, small-to-large consolidated areas (darker areas) appear with associated areas of white below the consolidated area (white lung). The darkening of the consolidated areas signals the loss of aeration and the transition of these areas toward acoustic properties similar to soft tissue over the entire area represented by the consolidation itself. Beyond the consolidations, the appearance of areas of white lung signals the presence of areas not yet

Figure 2. Lung US images obtained with linear (A and B) and convex (C and D) transducers. The pleura lines (indicated by red arrows) is continuous. Below, horizontal artifacts (indicated by blue arrows) may be visible. This pattern is classified as score 0.

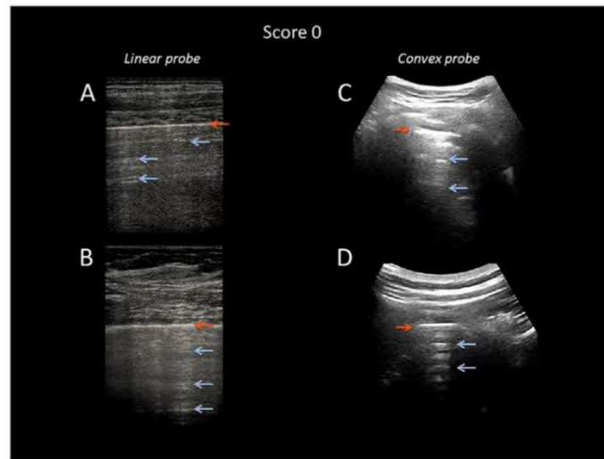


Figure 3. Lung US images obtained with linear (A) and convex (B) transducers. The pleural line is not continuous. Below the point of discontinuity (indicated by red arrows), vertical areas of white are visible (indicated by blue arrows). This pattern is classified as score 1.

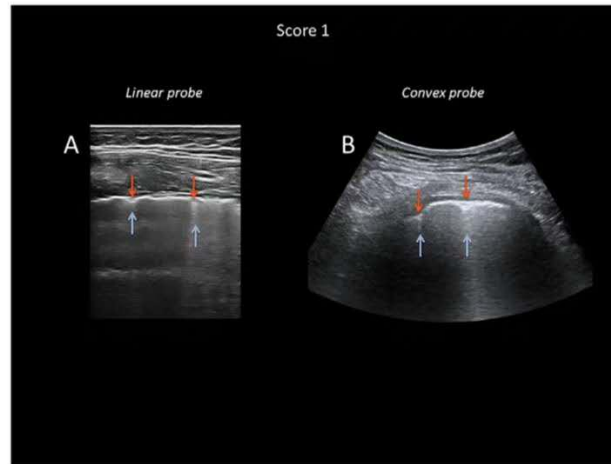
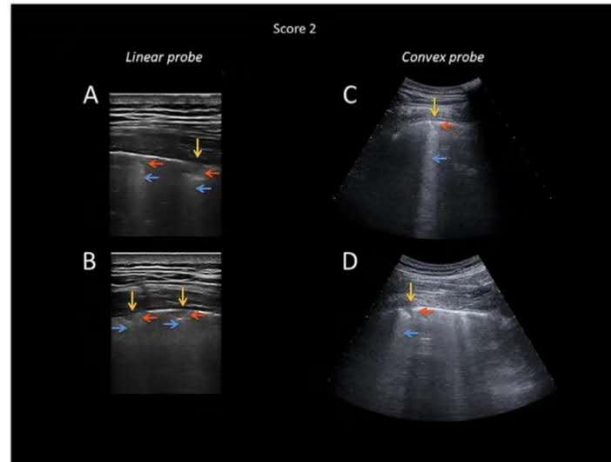


Figure 4. Lung US images obtained with linear (A and B) and convex (C and D) transducers. The pleural line is severely broken. Below the point of discontinuity (indicated by orange arrows), small consolidated areas (darker areas indicated by red arrows) appear with associated areas of white (indicated by blue arrows) in correspondence with the consolidations. This pattern is classified as score 2.



fully deaerated, where air inclusions are still present but embedded in tissuelike material. This highly scattering environment can explain this peculiar pattern.^{3,5,7}

- Score 3: The scanned area shows dense and largely extended white lung with or without larger consolidations.

At the end of the procedure, the clinician will write for each area the highest score obtained (eg, quadrant 1, score 2; quadrant 10, score 1; and so on).

International Database for Data Storage, Image Analyses, and Artificial Intelligence Studies

We strongly encourage the scientific community to embrace the development of a protected, internationally available database that allows uploading images and videos of patients with COVID-19 (radiography, US, and computed tomography). This will speed the development of dedicated pattern recognition algorithms able to recognize COVID-19-related pathologic findings, allow for comparisons between different

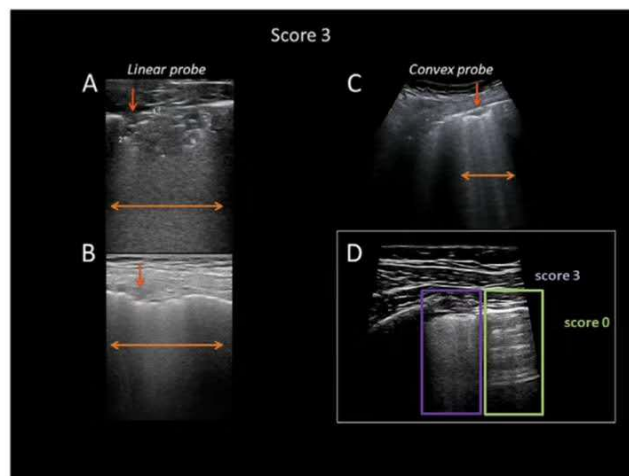
centers, and foster the development of telemedicine programs (including remote evaluation of images, clinical advice, and case discussions) and telematic teaching programs.

Here is the link to our database: <https://covid19.disi.unitn.it/iclusdb>.

Discussion and Conclusions

COVID-19 is a worldwide health challenge, involving not only health but also economics and social behaviors. For the first time in the era of modern medicine, the whole world is facing the same threat. This can give us the opportunity to change our research approach: the time has probably come to share our knowledge and plan the best care altogether. The aim of this article is thus to share our experience and to propose a standardization with respect to the use of LUS in the treatment of patients with COVID-19. The article introduces the detailing of landmarks and

Figure 5. Lung US images obtained with linear (A and B) and convex (C) transducers. The pleural line is severely broken. Below the point of discontinuity, large consolidated areas (darker areas indicated by red arrows) appear with a generalized white lung pattern (indicated by orange arrows). This pattern is classified as score 2. In the box at the right bottom (D), a LUS image is shown where the edge between a score of 0 (green box) and a score of 3 (purple box) pattern is clearly visible.



imaging settings to the acquisition protocol and presents a scoring mechanism developed within our group. We further emphasize the need for a shared database, which is necessary to foster further developments and to disseminate the results achieved.

References

1. Mojoli F, Bouhemad B, Mongodi S, Lichtenstein D. Lung ultrasound for critically ill patients. *Am J Respir Crit Care Med* 2019; 199:701–714.
2. Mayo PH, Copetti R, Feller-Kopman D, et al. Thoracic ultrasonography: a narrative review. *Intensive Care Med* 2019; 45:1200–1211.
3. Soldati G, Demi M, Smargiassi A, Inchingolo R, Demi L. The role of ultrasound lung artifacts in the diagnosis of respiratory diseases. *Expert Rev Respir Med* 2019; 13:163–172.
4. Soldati G, Smargiassi A, Mariani AA, Inchingolo R. Novel aspects in diagnostic approach to respiratory patients: is it the time for a new semiotics? *Multidiscip Respir Med* 2017; 12:15.
5. Demi M, Prediletto R, Soldati G, Demi L. Physical mechanisms providing clinical information from ultrasound lung images: hypotheses and early confirmations. *IEEE Trans Ultrason Ferroelectr Freq Control* 2020; 67:612–623.
6. Demi L, van Hoeve W, van Sloun RJG, Soldati G, Demi M. Determination of a potential quantitative measure of the state of the lung using lung ultrasound spectroscopy. *Sci Rep* 2017; 7:12746.
7. Soldati G, Demi M, Inchingolo R, Smargiassi A, Demi L. On the physical basis of pulmonary sonographic interstitial syndrome. *J Ultrasound Med* 2016; 35:2075–2086. <https://doi.org/10.7863/ultra.15.08023>.
8. Soldati G, Smargiassi A, Inchingolo R, et al. Lung ultrasonography and vertical artifacts: the shape of air. *Respiration* 2015; 90:86.
9. Soldati G, Smargiassi A, Inchingolo R, et al. Lung ultrasonography may provide an indirect estimation of lung porosity and airspace geometry. *Respiration* 2014; 88:458–468.
10. Peng QY, Wang XT, Zhang LN; Chinese Critical Care Ultrasound Study Group (CCUSG). Findings of lung ultrasonography of novel corona virus pneumonia during the 2019–2020 epidemic [published online ahead of print March 12, 2020]. *Intensive Care Med*. doi: <https://doi.org/10.1007/s00134-020-05996-6>.
11. Poggiali E, Dacrema A, Bastoni D, et al. Can lung US help critical care clinicians in the early diagnosis of novel coronavirus (COVID-19) pneumonia? *Radiology* 2020; 13:200847.
12. Soldati G, Smargiassi A, Inchingolo R, et al. Is there a role for lung ultrasound during the COVID-19 pandemic [published online ahead of print March 20, 2020]? *J Ultrasound Med*. doi: 10.1002/jum.15284.
13. Chen J, Qi T, Liu L, et al. Clinical progression of patients with COVID-19 in Shanghai China [published online ahead of print March 19, 2020]. *J Infect*. <https://doi.org/10.1016/j.jinf.2020.03.004>.
14. Buonsenso D, Pata D, Chiaretti A. COVID-19 outbreak: less stethoscope more ultrasound [published online ahead of print March 20, 2020]. *Lancet Respir Med*. [https://doi.org/10.1016/S2213-2600\(20\)30120-X](https://doi.org/10.1016/S2213-2600(20)30120-X).
15. Kampf G, Todt D, Pfaender S, Steinmann E. Persistence of coronaviruses on inanimate surfaces and their inactivation with biocidal agents. *J Hosp Infect* 2020; 104:246–251.
16. Miller DL, Dong Z, Dou C, Raghavendran K. Pulmonary capillary hemorrhage induced by different imaging modes of diagnostic ultrasound. *Ultrasound Med Biol* 2018; 44:1012–1021.